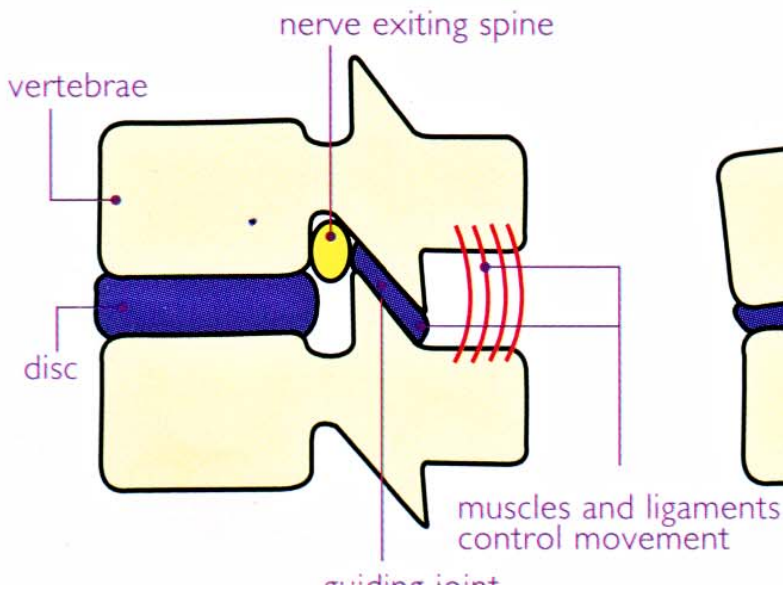


Spinal Malfunction

Normal

(two spinal bones viewed side-on)



Subluxation

